

## HEURISTICS AND CHEST X-RAY IMAGE SEGMENTATION FOR DENSENET, A TUBERCULOSIS DETECTION SYSTEM BASED ON THE MULTI-SCALE ATTENTION TECHNIQUE

Dipali Himmatrao Patil<sup>1</sup> and Dr. Amit Gadekar<sup>2</sup>

<sup>1</sup> Ph.D. scholar, Sandip University, Nashik

<sup>2</sup> Associate Professor, Sandip University Nashik

<sup>1</sup>patil.dipali07@gmail.com

<sup>2</sup>amit.gadekar@sandipuniversity.edu

### Abstract:

Tuberculosis (TB) is a disease that, if left untreated for an extended period of time, can ultimately be fatal. Early TB detection can be aided by using a deep learning ensemble. In previous work, ensemble classifiers were only trained on images that shared similar characteristics. It is necessary for an ensemble to produce a diverse set of errors in order for it to be useful; this can be accomplished by making use of a number of different classifiers and/or features. In light of this, a brand-new framework has been constructed in this study for the purpose of segmenting and identifying TB in human Chest X-ray. It was determined that searching traditional web databases for chest X-ray was necessary. At this point, we pass the photos that we have collected over to Swin ResUnet3 so that they may be segmented. After the segmented chest X-ray have been provided to it, the Multi-scale Attention-based Densenet with Extreme Learning Machine (MAD-ELM) model will be applied in the detection stage in order to effectively diagnose tuberculosis from human chest X-ray. This will be done in order to maximize efficiency. Because it increased the variety of errors made by the basic classifiers, the supplied variation of the approach that was proposed was able to detect tuberculosis more effectively. The proposed ensemble method produced results with an accuracy of 94.2 percent, which are comparable to those obtained by past efforts.

**Keyword:** Tuberculosis (TB), Chest X-ray, Multi-scale Attention-based Densenet with Extreme Learning Machine (MAD-ELM), TB detection, accuracy, sensitivity.

### 1. Introduction

One of the most major health issues facing people all over the world is tuberculosis. To this day, tuberculosis is one of the leading causes of death in both men and women [9]. It is referred to as an asymptomatic disease when it is in its early stage and does not display any visible symptoms. According to the findings of the International Agency for Tuberculosis Research (IARC), tuberculosis is responsible for 25% of all incident illnesses cases detected in humans in both developed and developing nations [10]. In terms of the number of people who ultimately succumb to the disease, tuberculosis is the fifth most prevalent cause of death. It is the major cause of mortality among human patients suffering from tuberculosis in impoverished nations [11]. It is responsible for more deaths than any other disease combined, and it is the second largest cause of death among humans in developed countries, behind only tuberculosis of the lung. In most cases, the causes of tuberculosis are unable to be identified with absolute certainty [12]. To this day, medical professionals and specialists are unable to provide a definitive explanation for why tuberculosis is more prevalent in certain humans than

in others [13]. Despite this, there are a number of common facts and symptoms that point to the possibility of tuberculosis. Pain in specific locations is a common symptom of tuberculosis, which can be caused by a number of different factors. In the vast majority of instances, the presence of a single symptom does not automatically indicate the presence of tuberculosis. Yet, the presence of any of the symptoms should serve as a potent incentive for the human to participate in the routine tuberculosis testing procedure [15]. The majority of these symptoms, if not all of them, do not emerge in the early stages of development. Hence, making an accurate diagnosis of tuberculosis in its early stages would be a difficult challenge.

The mortality rate of this condition can be significantly lowered via early diagnosis and treatment. Hence, having regular screenings can assist in the early detection of tuberculosis, so preventing the disease from spreading to surrounding normal tissues or to other organs [16]. One of the most important areas of research in the field of medical image processing is the early diagnosis of tuberculosis using digital chest X-rays [17]. Chest X-rays are an effective screening tool that may also be utilized to identify any abnormalities that may be present throughout the region. The mortality rate that is caused by tuberculosis can be controlled if the procedure of classifying lesions, which may be either malignant or benign, is carried out in the correct manner [18]. We should be able to bring this rate down quite a little with the assistance of this procedure. This procedure appears to be difficult, according to the observations that have been made [19]. The occurrence of faults in the process of recognizing noise pixels as false positives is the reason why this is the case. X-ray The Chest X-ray that are obtained throughout the tuberculosis examination process serve an essential role. They provide evidence of tuberculosis, which needs to be addressed as soon as possible. It is necessary to make the necessary improvements in them, which will further assist in helping to lessen the issues [20]. An chest X-ray provides an image of low quality that needs to be improved in order to be more clearly characterized. Performance measurements make it impossible to use pre-processing techniques to significantly enhance an chest X-ray image. This eliminates one potential use for these approaches. Screening comes with a considerable danger of producing false positive and negative results, despite the fact that it might be beneficial. The radiographer's manual detection of screening chest X-rays is not only laborious, expensive, and time-consuming, but it also results in a high percentage of false-positive findings [21]. On the other hand, the fact that tissue is variable and experts are scarce making the detection process simpler tests are thought to be the finest choice because it is one of the most trustworthy imaging programmed that can be used to diagnose the condition.

TB disease can affect every organ system in the body. The lungs are the most usually affected location associated to chest TB, however the disease can affect any part of the lungs. Chest radiography allows for the detection of many different types of disorders, including pulmonary consolidation, pneumothorax, pleural effusion, cardiac hypertrophy, nodules, infiltration, atelectasis, and emphysema. CAD systems are able to identify these diseases. The anatomy of the chest is seen in figure 1, which may be found here.

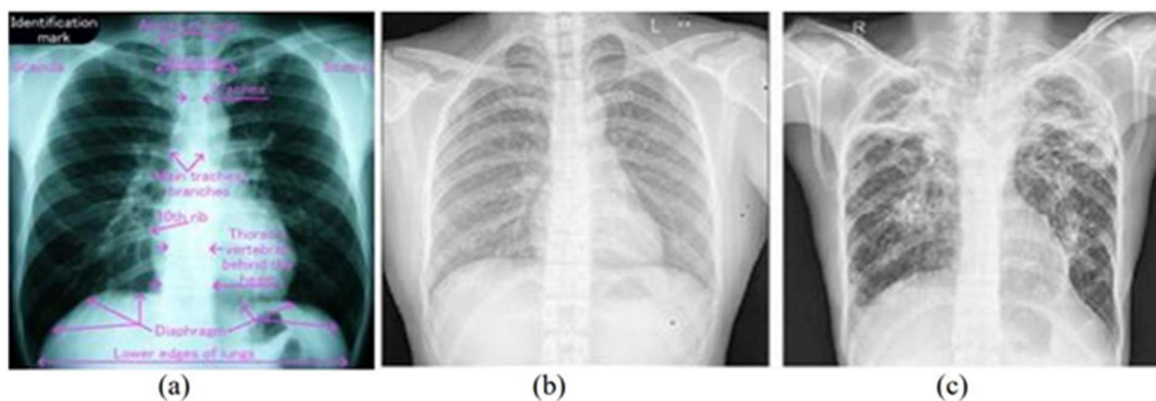


Figure 1. Chest X-ray image a) Chest anatomy b) A healthy chest X-ray image c) Tuberculosis with multiple cavitation Chest X-ray.

In today's world, the introduction and proliferation of deep learning models can make help more effective because these models have demonstrated exceptional achievements in a variety of domains. Radiologists are increasingly turning to and requesting a strategy known as deep learning because it helps them make more precise diagnoses and improves their ability to accurately anticipate patient outcomes [22]. It may be possible to achieve higher classification accuracy by developing ensemble methods that combine a number of different deep learning approaches. Deep learning is a strategy that is most commonly utilised to clean, repair, and detect flaws or disadvantages that are caused by machine learning. Deep learning-based improvement works on the entire image as well as improving the image one pixel at a time to produce better results. The development of deep learning and representation techniques has led to the emergence of automated methods [23]. Digital, ultrasonic, and magnetic resonance imaging are the types of modalities that are utilised for imaging the most frequently. Many of these methods are currently being digitised, which opens the door to the potential of putting deep learning into practice. Recent developments in methods of deep learning have had a significant impact on the diagnostic capabilities of

CAD systems [24]. Automated deep learning methods can be easily trained to achieve high accuracy on a variety of platforms. These methods show a great deal of potential for enhancing clinical tools in order to reduce the number of false positive and false negative screening findings. Improvements of a basic nature have been demonstrated by deep learning in image-based disease diagnosis and detection. The application of deep learning to the prognosis of tuberculosis exceeds other standard machine learning techniques. Using genetic profiles and phenotype data, deep learning frameworks have also been applied to the diagnosis, classification, and therapy of tuberculosis [25].

## 2. Background:

Linh et al. [1] proposed a method in 2021 that uses state-of-the-art Machine Learning and Computer Vision algorithms to detect tuberculosis in CXR images. Develop a strategy by using three cutting-edge deep neural networks (a modified EfficientNet, a modified original Vision Transformer, and a modified Hybrid EfficientNet with Vision Transformer) as the primary classification engines. In addition, you should utilise a variety of augmentation methods to strengthen the educational procedure. We put the proposed method to the test on a sizable dataset we assembled by merging several publicly available ones. The resulting dataset has

been partitioned into a training set (80%), a validation set (10%), and a testing set (10%). We compared our method with two advanced platforms to learn more about both. The outcomes were promising, with ViT Base EfficientNet B1 224 achieving the highest accuracy of 97.72% and the highest AUC of 100%. In terms of quality measures, our designed tool performs better than the considered baselines, as shown by our trial results.

In 2020, Seelwan et al. [2] proposed a Deep Convolutional Neural Network (DCNN) model trained on a Tuberculosis (TB)-specific chest x-ray (CXR) dataset from one group and evaluated on a non-TB-specific CXR dataset from a different community. The DCNN model had an AUC for TB detection of 0.9845 and 0.8502 in the training and intramural test sets, respectively, using the Shenzhen hospital database. However, the supervised DCNN model's AUC plummeted substantially to 0.7054 on the ChestX-ray8 dataset. The final DCNN model estimated that 36.51 percent of aberrant radiographs in the ChestX-ray8 dataset were associated to TB using cut points at 0.90, which implied 72 percent sensitivity and 82 percent specificity in the Shenzhen dataset. It's possible that the diagnostic accuracy of a supervised deep learning model trained on data collected from one population won't transfer to another. Before being applied elsewhere, it is important to investigate the following: the technical specifications of CXR pictures; the distribution of disease severity; the shift in the distribution of datasets; and the prevalence of overdiagnosis.

While training models to automatically infer TB from chest X-ray pictures, Vasundhara et al. [3] propose introducing a progressive resizing in 2022. The Score-Cam technique was used to draw attention to the areas of the chest X-rays that are most relevant to making an accurate diagnosis, and the ImageNet re-tuned Normalization-Free Networks (NFNets) was trained for classification. For both binary and multiclass classification, the suggested method is designed to offer precise diagnostics. Using a multiclass classification dataset, the trained models obtained an accuracy of 96.91 percent, an area under the curve (AUC) of 99.38 percent, a sensitivity of 91.8 percent, and a specificity of 98.42 percent. Both the accuracy and AUC for binary classification have been attained by the models to be in the top-1 percentile of inference metrics. The findings show that the proposed strategy can be utilised to help radiologists make secondary decisions in a clinical situation.

Urooj et al. [4] proposed in 2022 combining Chest X-ray pictures and stochastic learning using an artificial neural network (ANN) model to create an effective tuberculosis diagnosis system. Stochastic transfer functions or stochastic weights can be used with this method to add random functions into the network. The suggested method uses a randomization of the training dataset before each iteration to learn features from CXR images and optimise the parameters of an ANN model.

So that the algorithm can capture cross-channel information, direction-sensing, and position-sensing information, Xu et al. [5] propose coordinating the attention mechanism into a convolutional neural network (VGG16) in 2022. This would allow the algorithm to better identify and classify pulmonary tuberculosis images. To speed up the training process, we employed transfer learning and a frozen network. We tested how well our algorithm performed on a publicly available dataset from China's Shenzhen Third Hospital's tuberculosis categorization system. Data averaged over 5 rounds of cross-validation: F1 score =92.82%, accuracy =92.73 percent, AUC =97.71 percent, precision =92.73 percent, recall =92.83 percent. Our method outperformed ConvNet, FPN + Faster RCNN, and other methods that

claim to be CNN-based end-to-end solutions. Results from comparisons with other methods demonstrate that our approach is more accurate, meaning it can aid radiologists in making the ancillary diagnosis.

To consistently diagnose TB from chest X-ray pictures in 2020, Rahman et al. [6] suggest a method that incorporates image preprocessing, data augmentation, image segmentation, and deep-learning classification. A database of 3500 TB-infected and 3500 normal chest X-ray pictures was compiled for this study using many publicly available datasets. We trained, verified, and evaluated nine deep CNNs using their pre-learned initial weights to distinguish between TB and non-TB normal cases. In this study, we tested three distinct approaches, including two different U-net models for X-ray picture segmentation, an X-ray image classification method, and a segmented lung image. ChexNet was the top performing model for diagnosing tuberculosis in X-ray pictures, with accuracy of 96.47%, precision of 96.47%, sensitivity of 96.62%, F1-score of 96.47%, and specificity of 96.51%. Classification using segmented lung pictures, however, exceeded that using entire Chest X-ray, with DenseNet201 achieving 98.6% accuracy, 98.57% precision, 98.56% sensitivity, 98.56% F1-score, and 98.54% specificity. In addition, the authors employed a visualisation method to verify that CNN acquires its superior detection accuracy from training on the segmented lung areas. With its cutting-edge performance, the proposed technology has the potential to speed up the computer-assisted diagnosis of tuberculosis.

In 2023, Ahmed Iqbal et al. [7] published a unique TB-UNet based on dilated fusion blocks (DF) and Attention blocks (AB) for reliable segmentation of lungs regions, with the best results in terms of precision (0.9574), Recall (0.9514), F1 score (0.8988), IoU (0.8168), and Accuracy (0.9770). For accurate tuberculosis picture classification, we propose using a network architecture called TB-DenseNet, which consists of five dual convolution blocks, a DenseNet-169 layer, and a feature fusion block. Three different chest X-ray (CXR) datasets have been used in the tests, with both segmented and original pictures being fed into TB-DenseNet for improved categorization. Further tests were conducted on the suggested approach using pneumonia, COVID-19, and tuberculosis as the target pathogens. Precision (0.9567), recall (0.9510), score, and accuracy (all 0.9538) all reached their maximum (0.9510). According to the findings, our proposed strategy outperforms the current gold-standard approaches.

Five commercial AI systems for tuberculosis triage were evaluated by Zhi et al. [8] in 2021, utilising a big dataset that had not been utilised to train any AI algorithms before. Methods Dhaka, Bangladesh residents aged 15 and up who presented or were referred to one of three tuberculosis screening sites between May 15, 2014 and October 4, 2016 were enlisted in a time-staggered fashion. Participants were given a digital posterior-anterior chest x-ray and an Xpert MTB/RIF test after a verbal screening for symptoms. All chest x-rays were read by one of three board-certified radiologists and one of five commercial artificial intelligence (AI) algorithms (CAD4TB, InferRead DR, Lunit INSIGHT CXR, JF CXR-1, and XR). We compared the AI systems' results against those of one another, those of the radiologists, and the World Health Organization's Target Product Profile (TPP) for triage testing.

Implementers' decisions about which software to use and which abnormality scores to use as cutoffs were informed by a new evaluation framework that included sensitivity, the fraction of Xpert tests avoided, and the number of tests required.

### 3. Problem Statement

The infectious disease tuberculosis is caused by a bacterium called *Mycobacterium tuberculosis*. This bacterial infectious condition is easily treatable with antibiotics. If tuberculosis is diagnosed and treated quickly, it can be cured. In order to detect and screen for pulmonary tuberculosis, chest X-rays (CXR) are routinely used. Many prior works were utilised; characteristics and difficulties of these efforts are listed in Table 1. While DNN [1] reduces the feature map size and demands a huge amount of data in an effort to increase prediction accuracy, it also calculates high hyperparameters. Despite its ability to tackle complicated issues and deliver better performance, DCNN [2] is more computationally intensive and prone to overfitting, ballooning gradients, and class imbalance. While DL [3] may be used to categorise images with a high accuracy rate, it is a network that is highly sensitive to noisy data and is computationally intensive. ANN[4] ensures convergence and boosts performance, but it's erratic and uses twice as many parameters per neuron as other methods. Overfitting, an inflating gradient, and class imbalance are all side effects of CNN [5], which reduces false positives in the entire model and improves classification performance. CNN [6] is being progressively dismantled, which means that it will not abruptly cease to function, and similarly, these networks are being gradually dismantled, but they are not reliable and the problem statement is very difficult to grasp. The network's lifespan is unknown and it has large processing requirements, whereas CNN [7] stores the complete information and has more power to work several jobs. Artificial intelligence [8] is risk-free and more productive than competing approaches, but it's also costly and may pose issues for the next generation. These difficulties prompted us to develop an X-ray method for diagnosing tuberculosis.

**Table 1: Features and challenges of chest X-ray classification for tuberculosis detection**

Author [citation]	Methodology	Features	Challenges
Linh <i>et al.</i> [1]	DNN	<ul style="list-style-type: none"> <li>It attempts to improve prediction accuracy.</li> <li>It determines high hyperparameters</li> </ul>	<ul style="list-style-type: none"> <li>It reduces the feature map size.</li> <li>A large amount of data is required.</li> </ul>
Seelwan <i>et al.</i> [2]	DCNN	<ul style="list-style-type: none"> <li>It can handle complex problems.</li> <li>It provides improved performance.</li> </ul>	<ul style="list-style-type: none"> <li>It causes overfitting, exploding gradient, and class imbalance.</li> <li>It has a greater computational burden.</li> </ul>
Vasundhara <i>et al.</i> [3]	DL	<ul style="list-style-type: none"> <li>It avoids the problem of exploding gradients.</li> <li>It is used to classify the images with a high accuracy rate.</li> </ul>	<ul style="list-style-type: none"> <li>It's a very sensitive network to noise data.</li> <li>It is computationally expensive</li> </ul>

Urooj <i>et al.</i> [4]	ANN	<ul style="list-style-type: none"> <li>• It guarantees convergence.</li> <li>• It provides improved performance.</li> </ul>	<ul style="list-style-type: none"> <li>• It is unpredictable.</li> <li>• It doubles the number of parameters for each neuron</li> </ul>
Xu <i>et al.</i> [5]	CNN	<ul style="list-style-type: none"> <li>• It decreases the false into a positive in the overall model.</li> <li>• It achieves superior classification performance</li> </ul>	<ul style="list-style-type: none"> <li>• It causes overfitting, exploding gradient, and class imbalance.</li> <li>• It has dice loss.</li> </ul>
Rahman <i>et al.</i> [6]	CNN	<ul style="list-style-type: none"> <li>• It gradually being broken down, which means that they will not suddenly stop working and these networks are gradually being broken down</li> </ul>	<ul style="list-style-type: none"> <li>• It is not reliable.</li> <li>• It is very difficult to understand the problem statement.</li> </ul>
Ahmed Iqbal <i>et al.</i> [7]	CNN	<ul style="list-style-type: none"> <li>• It stores the entire information.</li> <li>• It has more power to work more than one job.</li> </ul>	<ul style="list-style-type: none"> <li>• The duration of the network is unknown.</li> <li>• It has high computational requirements.</li> </ul>
Zhi <i>et al.</i> [8]	AI	<ul style="list-style-type: none"> <li>• It has zero risk.</li> <li>• It is more efficient compared to other methods.</li> </ul>	<ul style="list-style-type: none"> <li>• It is high cost.</li> <li>• This addiction to AI can cause problems for future generations.</li> </ul>

#### 4. Proposed Methodology

It is believed that tuberculosis is the primary cause of high death rates and has the second highest mortality rate of all varieties of tuberculosis that may be detected in humans. Tuberculosis has the second highest mortality rate. Chest X-ray are frequently analysed by skilled and well-trained radiologists in order to identify anomalies such as masses and micro-calcifications in the patient's breast tissue. The early detection of this dangerous condition, followed by an accurate diagnosis, can assist in the fight against it. It has been demonstrated that segmentation of lesions is a helpful source of information for the diagnosis and categorization of tuberculosis. A more exact localisation of the lesions can be obtained by the use of segmentation, which can help in the process of retrieving shape-related data. As a result, one of our primary goals was to create an innovative framework for the segmentation and identification of Chest X-ray specifically geared towards the detection of tuberculosis in human beings. The Chest X-ray that are desired will be retrieved from more conventional web resources. After the photos have been acquired, they will be sent on to the segmentation step,

where An ResUnet3+ will be used to segment them. So, the Chest X-ray that have been segmented will be sent to the detection stage. This is the stage where the Multi-scale Attention-based Densenet with Extreme Learning Machine (MAD-ELM) model will be used in order to efficiently detect tuberculosis from the Chest X-ray. The parameters obtained from the MAD-ELM will be optimised with the help of the recommended Improved Invasive Weed Optimization Algorithm (IIWO), as well as the Crisscross Optimization Algorithm (COA). In order to demonstrate how successful, the new model for detecting tuberculosis that was constructed with the assistance of deep learning is, it will be evaluated with the help of a number of models that are already in use. Figure provides a description of the architecture of the suggested model for detecting tuberculosis through the use of deep learning.

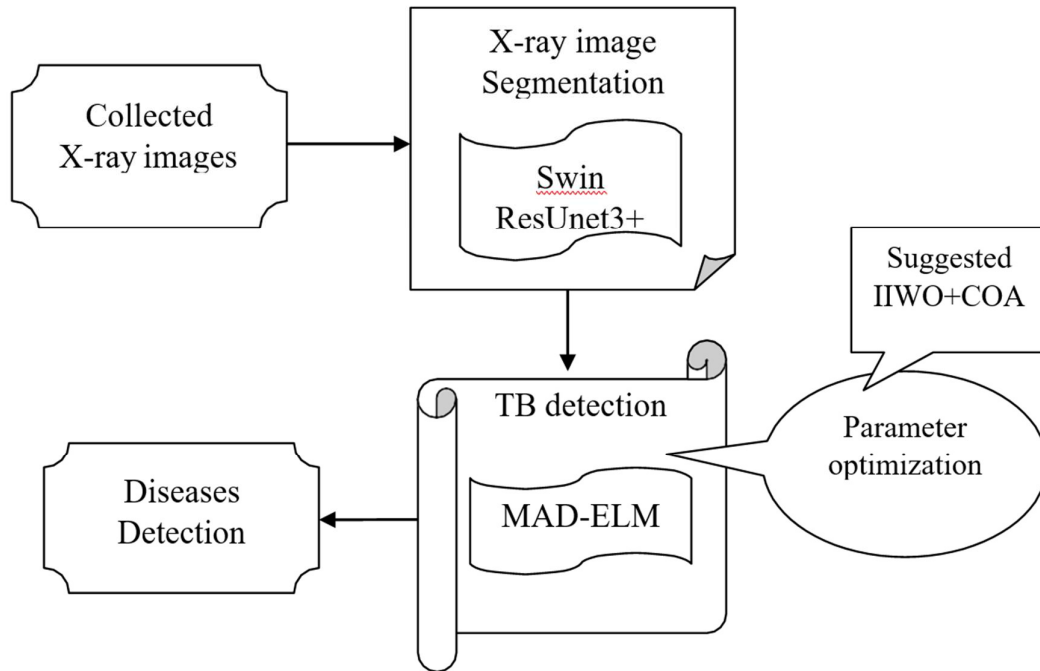


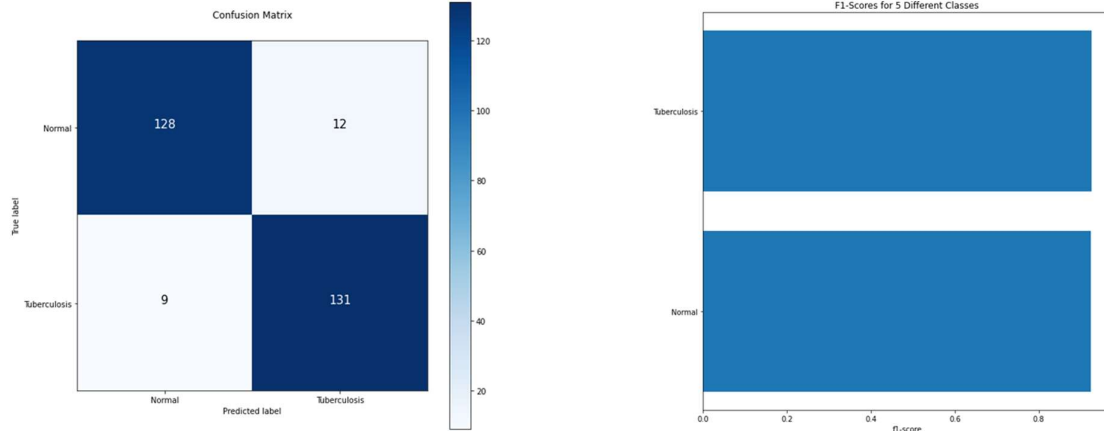
Figure 2: Architecture of the suggested Tuberculosis detection model using deep learning

### 5. Experiments and discussion

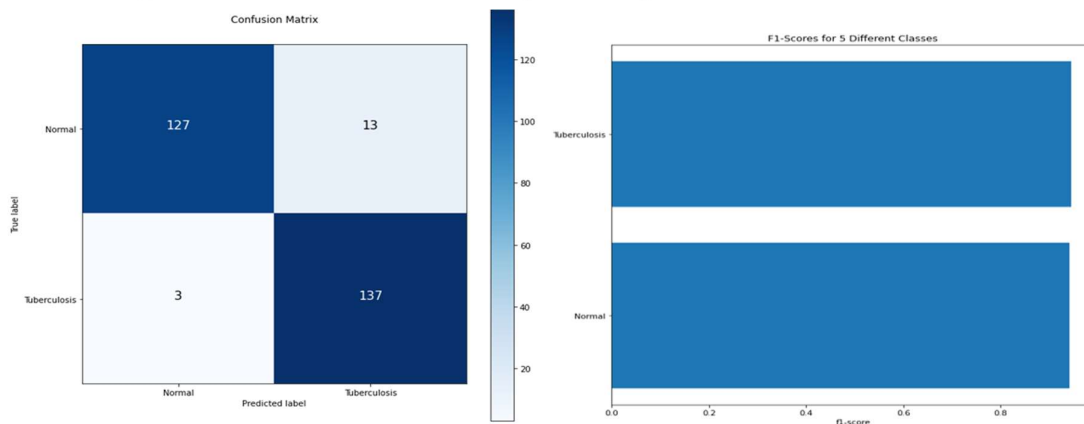
Experiments were carried out in order to evaluate the performance of the suggested method in comparison to the one that is already being used on chest X-ray, which can be accessed through an online media. The ability to extract shape-related properties is one of the benefits of segmentation, which can assist improve the accuracy of lesion localization. As a result, we decided to develop an original framework for the segmentation and identification of tuberculosis in Chest X-ray. The images that are required will be gathered from the typical online repositories. After the photos have been gathered, they will be sent on to the segmentation step, where The ResUnet3+ will be utilized for the segmentation process. In order to make an accurate diagnosis of tuberculosis using chest X-ray, a model called the Multi-scale Attention-based Densenet with Extreme Learning Machine will be applied to the images once they have been segmented. For the purpose of finding the optimal values for the MAD-ELM parameters, two different optimization algorithms—the Improved Invasive Weed Optimization Algorithm (IIWO) and the Crisscross Optimization Algorithm (COA)—have been suggested.



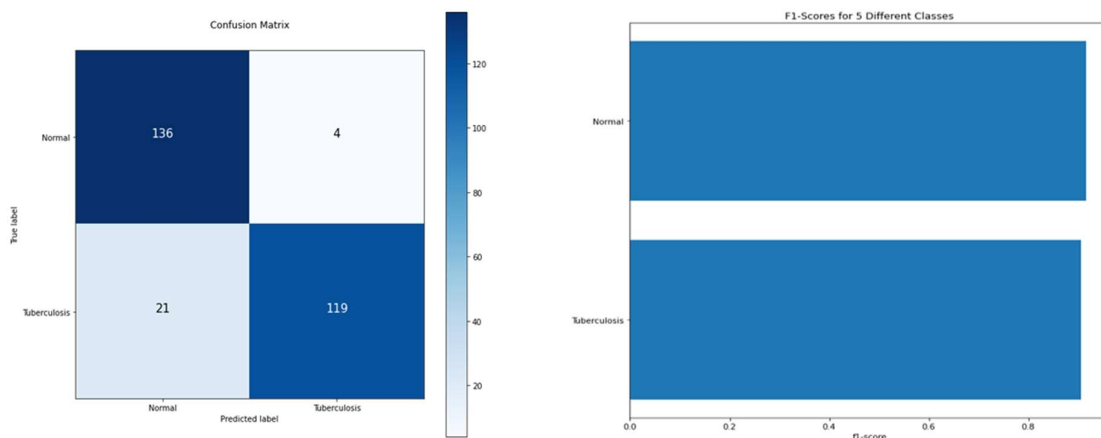
The effectiveness of the tuberculosis (TB) detection model that makes use of deep learning will be tested in comparison to numerous baseline methods. The following graphic illustrates the existing Classifier that is used to categories the photos, along with the confusion matrix of the current methodology and the suggested model, both of which make use of several key parameters.



**Figure 3: CNN Classifier to classify the images with Confusion matrix**



**Figure 4: Random Forest Classifier to classify the images with Confusion matrix**



**Figure 5: KNN Classifier to classify the images with Confusion matrix**

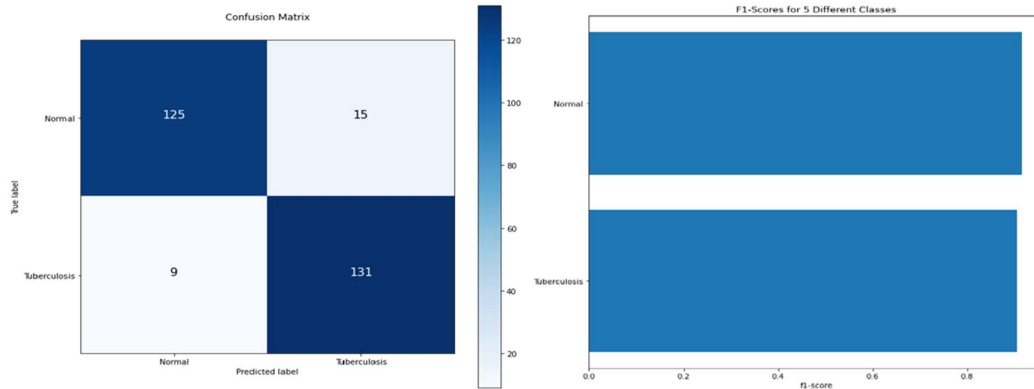


Figure 6: Decision Tree Classifier to classify the images with Confusion matrix

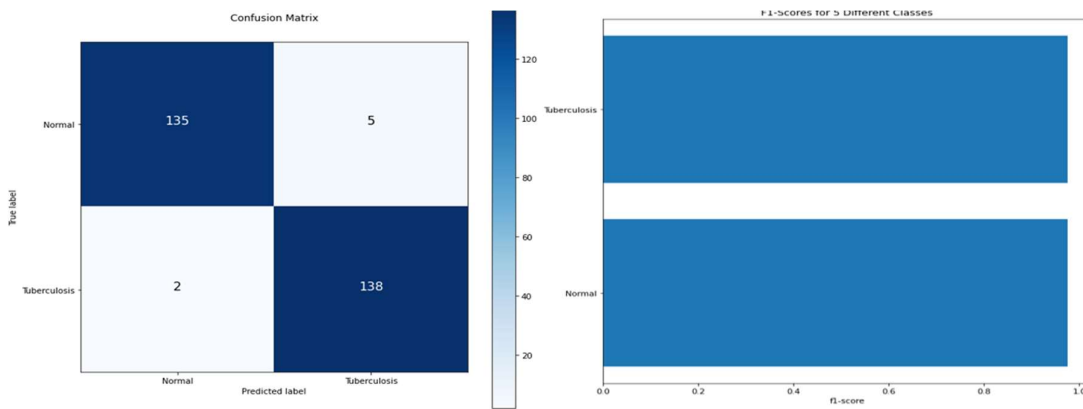


Figure 7: DNN Classifier to classify the images with Confusion matrix

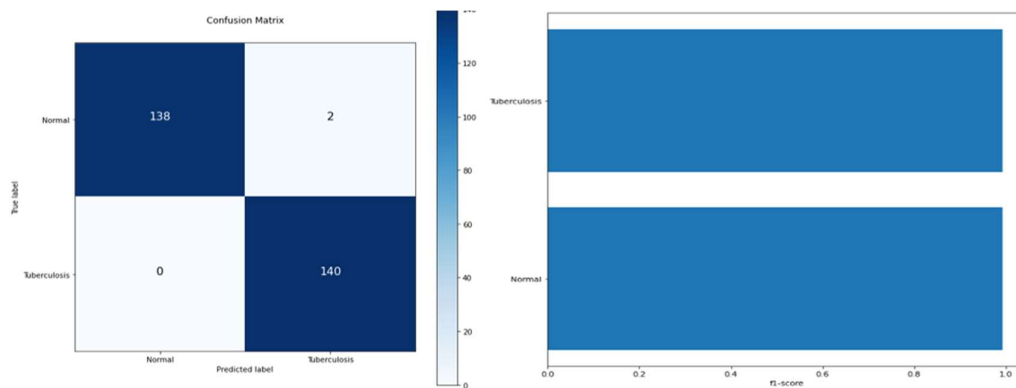


Figure 8: Hybrid approach (IIWO+COA) Classifier to classify the images with Confusion matrix

## 6. Comparative analysis

The comparative analysis of the designed model is carried out in terms of "various classifiers," as represented in Table accordingly. This is done so that the results may be compared. The proposed method has an accuracy that is 1.7%, 0.8%, 1.39%, 1.8%, 6.2%, 5.25%, 5%, and 5.9% more advanced than any other methodology that is currently in use, correspondingly. The FPR of the suggested strategy is higher than another method by 14%, 11.7%, 16.6%, 23%, 48%, 44%, 44%, and 47.3% respectively. In a similar vein, the proposed model demonstrates

an effective performance in terms of a variety of parameters when contrasted with a variety of classification-based methods.

**Table 2: Overall Performance analysis for the designed model in with diverse classifies**

Measures	CNN	DNN	KNN	Random	DT	Hybrid model
“Accuracy”	0.887	0.895	0.896	0.889	0.076321	0.942
“Recall”	0.887526	0.895706	0.897751	0.889571	0.07362	0.94274
“F1-Score”	0.884811	0.892966	0.894094	0.88685	0.923679	0.940816
“Precision”	0.882114	0.890244	0.890467	0.884146	0.079268	0.9389

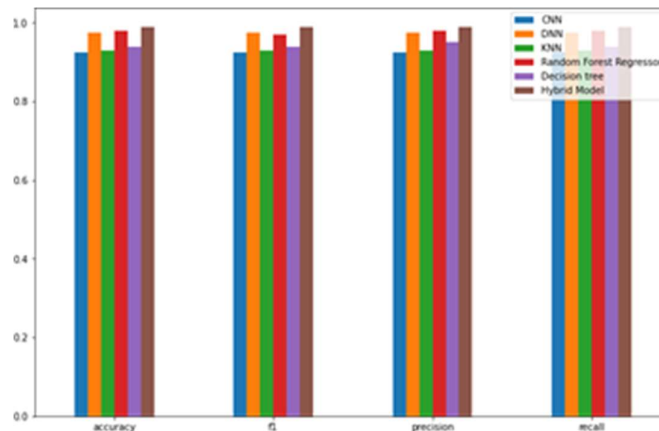


Figure 9: Comparative analysis of proposed approach using existing with some parameters

**7. Conclusion:**

In this work, a framework is presented for segmenting and identifying tuberculosis in Chest X-ray of human patients. It was determined that searching traditional web databases for chest X-ray was necessary. At this point, we pass the photos that we have collected over to Swin ResUnet3 so that they may be segmented. After it has been provided with segmented chest X-ray, the Multi-scale Attention-based Densenet with Extreme Learning Machine (MAD-ELM) model will be applied in the detection stage in order to effectively diagnose tuberculosis from human images. This will take place after the model has been given the segmented images. We suggest enhancing the MAD parameters by optimizing the Crisscross Optimization Algorithm and the Improved Invasive Weed Optimization Algorithm (IIWO). ELM's (COA). By expanding the range of mistakes that the foundational classifiers can make, the form of the proposed method that was presented here was able to improve TB identification. When ensembles of classifiers were utilized, each of which had been trained on a distinct set of features generated from a different set of photos, all three aspects of detection performance accuracy, sensitivity, and specificity—were significantly improved. As a consequence of this, it provides additional support for the primary hypothesis of this research.

**References:**

[1] Linh T. Duong, Nhi H. Le, Toan B. Tran, Vuong M. Ngo and Phuong T. Nguyen "Detection of tuberculosis from chest Chest X-ray: Boosting the performance with vision transformer and transfer learning" Expert Systems With Applications Vol. 184, pp.115519, 1 December 2021.

- [2] Seelwan Sathitratanaheewin, Panasun Sunanta, and Krit Pongpirul "Deep learning for automated classification of tuberculosis-related chest X-ray: dataset distribution shift limits diagnostic performance generalizability" August 01, 2020.
- [3] Vasundhara Acharya, Gaurav Dhiman, Krishna Prakasha, Pranshu Bahadur, Ankit Choraria, Sushobhitha M, Sowjanya J, Srikanth Prabhu, Krishnaraj Chadaga, Wattana Viriyasitavat, and Sandeep Kautish "AI-Assisted Tuberculosis Detection and Classification from Chest X-Rays Using a Deep Learning Normalization-Free Network Model" *Computational Intelligence and Neuroscience*, pp.19, 2022.
- [4] S. Urooj, S. Suchetha, L. Krishnasamy, N. Sharma and N. Pathak, "Stochastic Learning-Based Artificial Neural Network Model for an Automatic Tuberculosis Detection System Using Chest X-Ray Images," *IEEE Access*, vol. 10, pp. 103632-103643, 2022.
- [5] T. Xu and Z. Yuan, "Convolution Neural Network With Coordinate Attention for the Automatic Detection of Pulmonary Tuberculosis Images on Chest X-Rays," *IEEE Access*, vol. 10, pp. 86710- 86717, 2022.
- [6] T. Rahman et al., "Reliable Tuberculosis Detection Using Chest X-Ray With Deep Learning, Segmentation, and Visualization," *IEEE Access*, vol. 8, pp. 191586-191601, 2020.
- [7] Ahmed Iqbal, Muhammad Usman and Zohair Ahmed "Tuberculosis chest X-ray detection using CNN-based hybrid segmentation and classification approach" *Biomedical Signal Processing and Control* Vol. 84, pp.104667, July 2023.
- [8] Zhi Zhen Qin MSc, Shari Ahmed MHE, Mohammad Shahnewaz Sarke, Kishor Pau, Ahammad Shafiq Sikder Adel, Tasneem Naheyan, Rachael Barrett and Sayera Banu "Tuberculosis detection from chest x-rays for triaging in a high tuberculosis-burden setting: an evaluation of five artificial intelligence algorithms" *The Lancet Digital Health* Vol. 3, pp. e543-e554, Issue 9, September 2021.
- [9] Malik, H., Anees, T and Din, M. "CDC\_Net: multi-classification convolutional neural network model for detecting COVID-19, pneumothorax, pneumonia, lung Cancer, and tuberculosis using chest X-rays". *Multimedia Tools Application* Vol.82, pp.13855–13880, 2023.
- [10] Santosh, K., Allu, S. and Rajaraman, S." Advances in Deep Learning for Tuberculosis Screening using Chest X-rays: The Last 5 Years Review". *Journal of Medical System* Vol.46, pp.82,2022.
- [11] Bakari, M., Arbeit, R.D.and Mtei." Basis for treatment of tuberculosis among HIV-infected patients in Tanzania: the role of chest x-ray and sputum culture". *BMC Infectious Disease* Vol.8, pp.32, 2008.
- [12] Van Cleeff, M., Kivihya-Ndugga, and L., Meme. "The role and performance of chest X-ray for the diagnosis of tuberculosis: A cost-effectiveness analysis in Nairobi, Kenya". *BMC Infectious disease* Vol.5, pp,111, 2005.
- [13] J. Melendez, B. van Ginneken, P. Maduskar, R. H. H. M. Philipsen, H. Ayles and C. I. Sánchez, "On Combining Multiple-Instance Learning and Active Learning for Computer-Aided Detection of Tuberculosis," *IEEE Transactions on Medical Imaging*, vol. 35, no. 4, pp. 1013-1024, April 2016.

- [14] R. Shen, I. Cheng, and A. Basu, "A Hybrid Knowledge-Guided Detection Technique for Screening Infectious Pulmonary Tuberculosis From Chest Radiographs, "IEEE Transactions on Biomedical Engineering, vol. 57, no. 11, pp. 2646-2656, Nov. 2010.
- [15] S. Jaeger "Automatic Tuberculosis Screening Using Chest Radiographs, "IEEE Transactions on Medical Imaging, vol. 33, no. 2, pp. 233-245, Feb. 2014.
- [16] T. Rahman et al., "Reliable Tuberculosis Detection Using Chest X-Ray With Deep Learning, Segmentation, and Visualization, "IEEE Access, vol. 8, pp. 191586-191601, 2020.
- [17] R. Khutlang, "Classification of Mycobacterium tuberculosis in Images of ZN-Stained Sputum Smears, "IEEE Transactions on Information Technology in Biomedicine, vol. 14, no. 4, pp. 949-957, July 2010.
- [18] A. F. M. Saif, T. Imtiaz, C. Shahnaz, W. -P. Zhu and M. O. Ahmad, "Exploiting Cascaded Ensemble of Features for the Detection of Tuberculosis Using Chest Radiographs, "IEEE Access, vol. 9, pp. 112388-112399, 2021.
- [19] S. Rajaraman and S. K. Antani, "Modality-Specific Deep Learning Model Ensembles Toward Improving TB Detection in Chest Radiographs, "IEEE Access, vol. 8, pp. 27318-27326, 2020.
- [20] Z. Ul Abideen, "Uncertainty Assisted Robust Tuberculosis Identification With Bayesian Convolutional Neural Networks," in IEEE Access, vol. 8, pp. 22812-22825, 2020.
- [21] Siddiqui, A.K.and Garg, V.K." An Analysis of Adaptable Intelligent Models for Pulmonary Tuberculosis Detection and Classification". SN COMPUTER SCIENCE. Vol.3, pp.34, 2022.
- [22] Picnicker, R.O., Soman and Saini, G.. "A Review of Automatic Methods Based on Image Processing Techniques for Tuberculosis Detection from Microscopic Sputum Smear Images". Journal Medical System Vol.40, pp.17, 2016.
- [23] Afzali, A., Babapour Mofrad, F and Pouladian, M. Contour-based lung shape analysis to tuberculosis detection: modeling and feature description. Medical Biological Engineering Computer Vol.58, pp.1965–1986,2020.
- [24] Dinesh Jackson Samuel, R., and Rajesh Kanna, B."Tuberculosis (TB) detection system using deep neural networks". Neural Computer and Application Vol.31, pp.1533–1545, 2019.
- [25] Yan, C., Wang, L., and Lin, J. "A fully automatic artificial intelligence–based CT image analysis system for accurate detection, diagnosis, and quantitative severity evaluation of pulmonary tuberculosis". European Radiology Vol.32, pp.2188–2199, 2022.
- [26] Afshin Faramarzi, Mohammad Heidarinejad, Brent Stephens and Seyedali Mirjalili, "Equilibrium optimizer: A novel optimization algorithm", Knowledge-Based Systems, Vol. 191, 2020.